

Bell-Ringer


- A 39 Year Old-Woman was found in her High-Rise Apartment on Monday. The Medical Examiner determined the cause of death to be strangulation second to blunt force trauma. The women was found in the tub, without clothing. All the windows in the apartment were open and the heat was turned of in the apartment. No forced entry was found on the doors to her apartment. Who is the killer? Why did the killer open the windows and turn off the heat?

Your Bones Have a Message

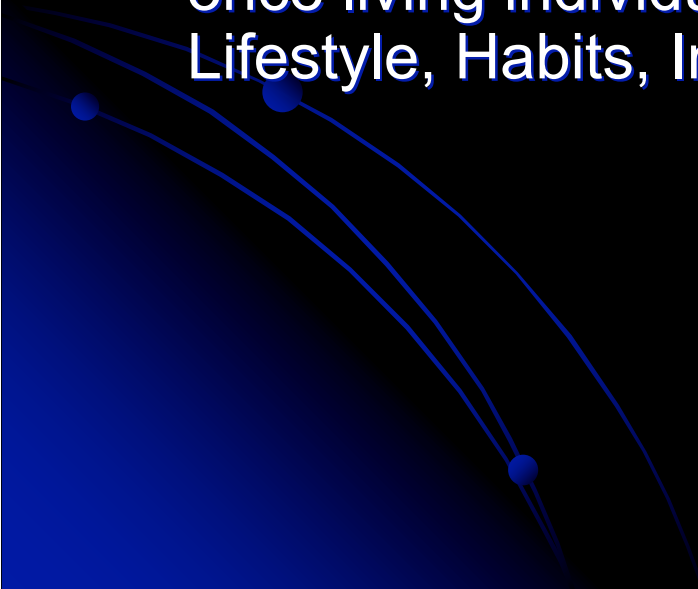
Forensic Anthropology



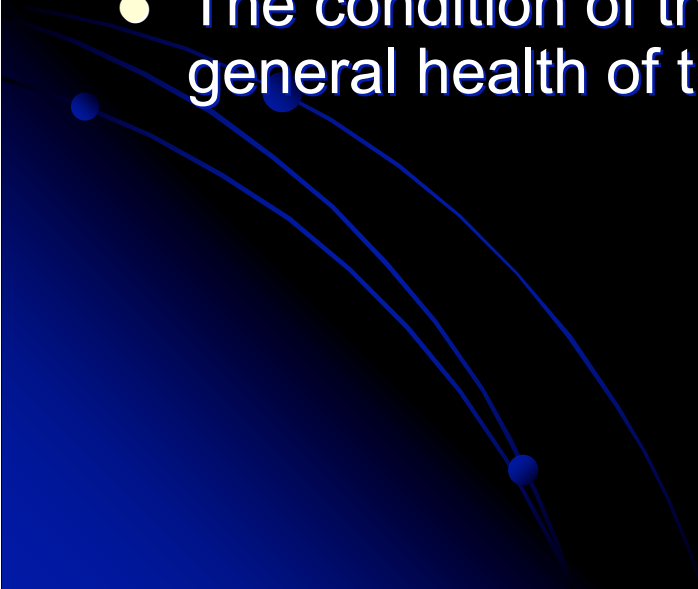
Introduction

- Specifically trained scientists can identify people by their skeletal remains.
 - If the entire skeleton cannot be located, scientist can use individual bones, bone fragments, and teeth to identify an unfamiliar body.
 - These scientists are called Forensic Anthropologists.
- 

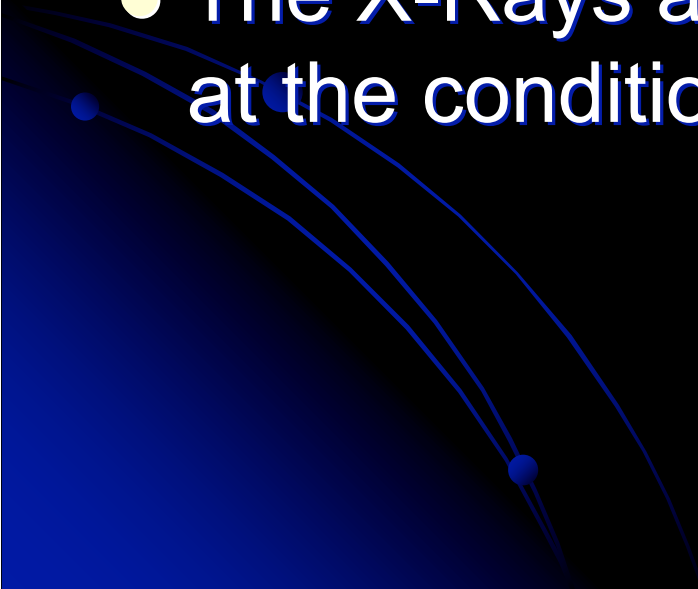
Sherlock Bones

- Forensic Anthropology was established as a certified science by the FBI in the 1930's
 - Forensic Anthropologists prefer to work with complete skeletons, but often only have access to individual bones or teeth.
 - A complete skeleton can reveal a great deal about the once living individual: Physical Characteristics, Health, Lifestyle, Habits, Injuries and even cause of death.
- 

Bones Continued...

- When unidentified human bones are located, they are carefully packaged and sent to the lab.
 - These experts attempt to develop a detailed bone and dental record from the remains.
 - Size and shape of certain bones can indicate the age, sex, height and build of an individual.
 - The condition of the bones can indicate disease and general health of the individual at the time of death.
- 

Therefore

- The Forensic Anthropologists carefully examines the bones and records all the information he/she can gather from an individual examination.
 - The X-Rays are used to get a closer look at the condition of the bones.
- 

Head and Hips

- The sex of the unknown individual can be determined from the skull and pelvis.
- Length of the arm and leg bones can be used to calculate the height of the human.
- Deviations in bones, such as the lipping at the end of the upper leg bone, indicate that an individual may have been an elderly person with arthritis (Inflammation of the Joint).
- Indentations of the teeth often indicate the presence of dental fillings at one time.
- A Comparison of the location and shape of these fillings may eventually be matched to a dental record of an individual.

Thanks for your attention

- Experiment Tomorrow
 - Missing Persons: A Lab on Forensic Anthropology
 - Complete Journal (Today)
 - Case Study: Ivan the Terrible
- 