



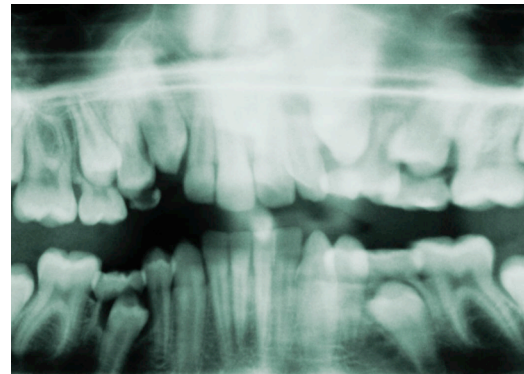
Teeth Marks and Forensics

03/29/2010

Forensic Science

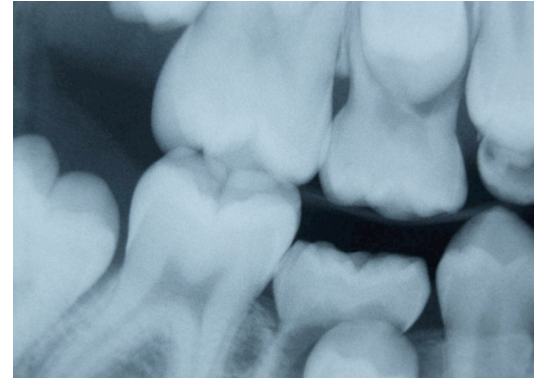
Bell-Ringer

- Bell-Ringer and Journal are due at the end of class.
- What is the hardest substance in the body.
- Can health history be determined from your teeth?




Summary

- History
- Body Identification
- Bite Mark Analysis
- Personal Injury/Dental Malpractice



History

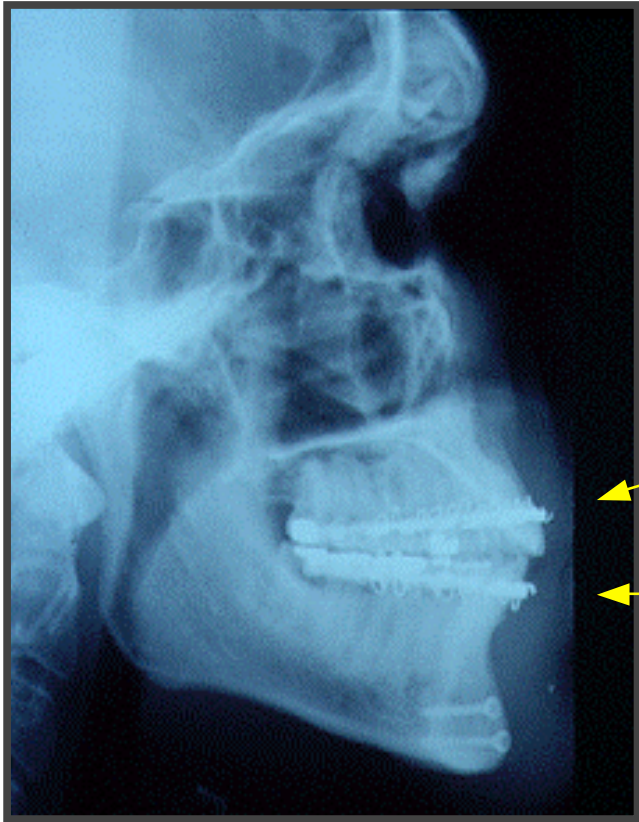


Body Identification

- Roman Emperor Claudius - wife wanted decapitated head of mistress
- Paul Revere – dentures of soldier

Bite Mark Analysis

- King William - bite in wax



Anatomy of Oral Cavity:

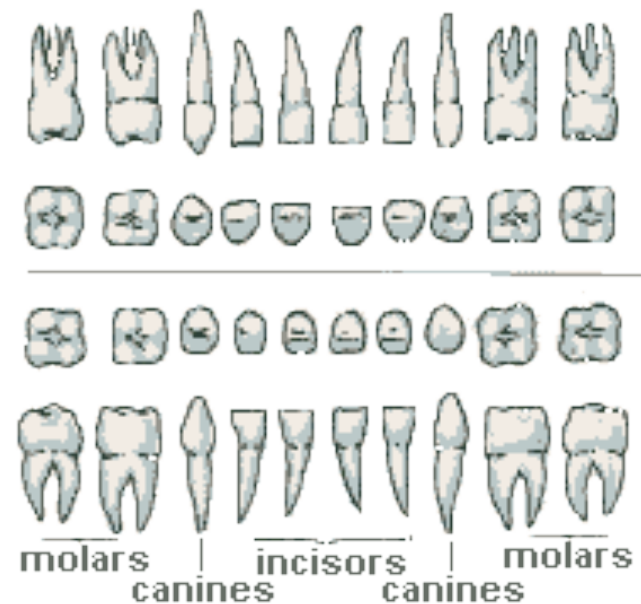
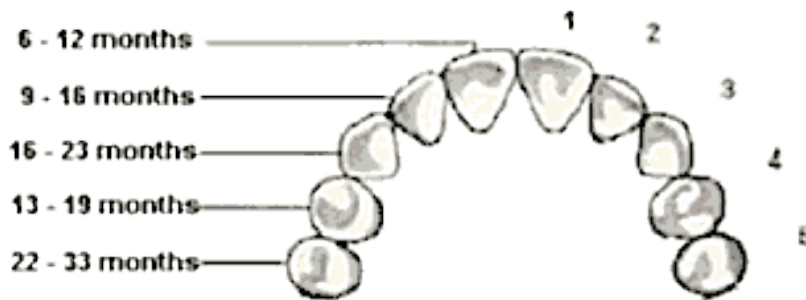
Maxilla – upper jaw

Mandible – lower jaw

Anatomy of Oral Cavity

Primary dentition

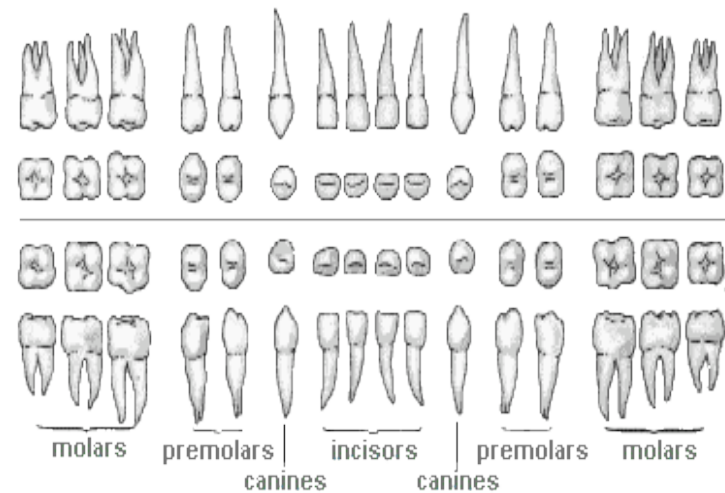
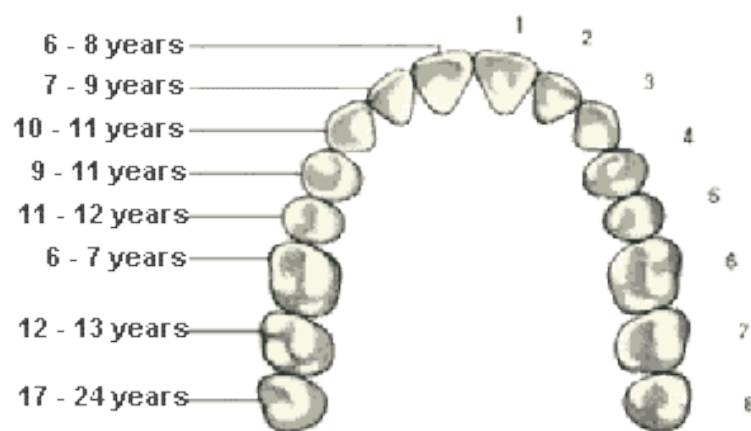
- Baby teeth or milk teeth
- 20 teeth



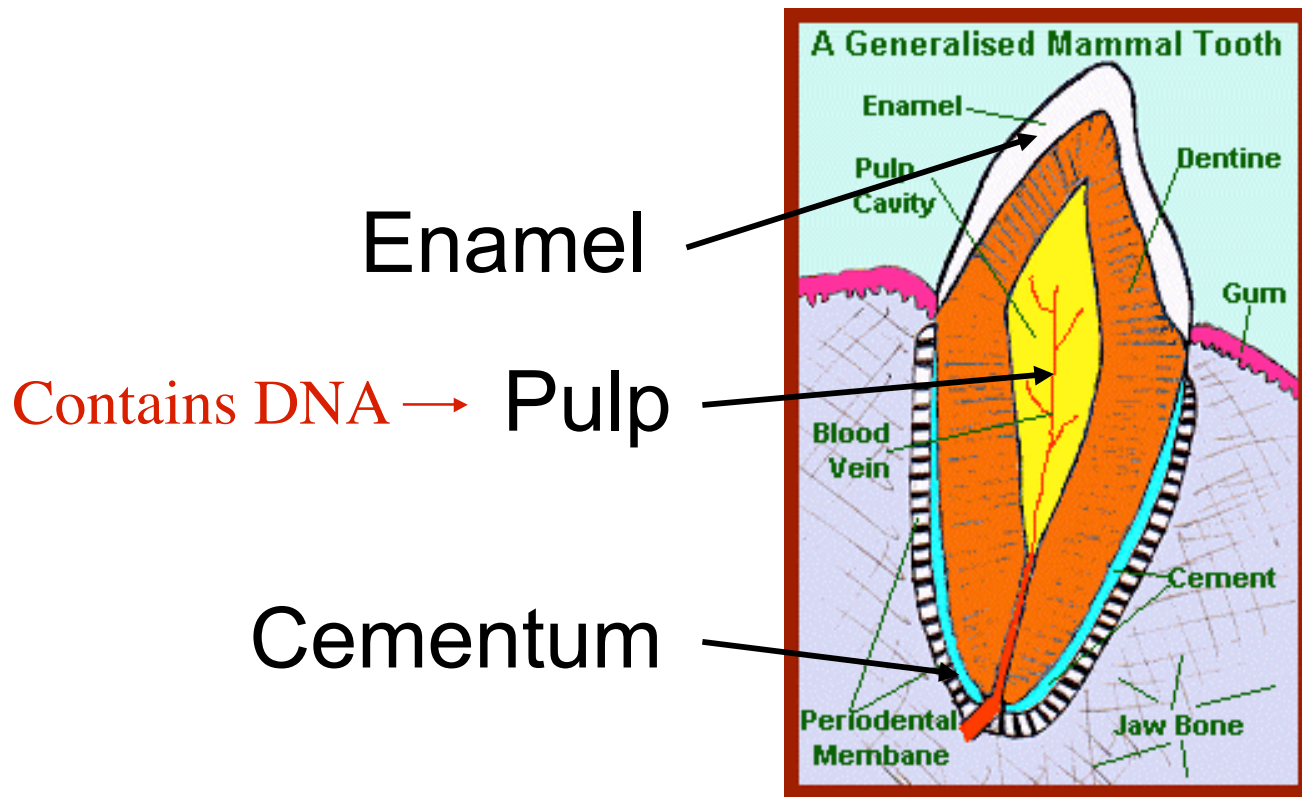
Anatomy of Oral Cavity

Permanent dentition

- Start at 6-8 years old
- 32 teeth

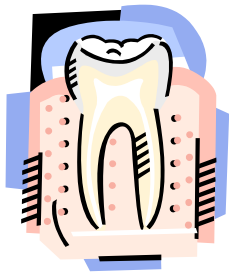

Anatomy of Tooth




T
Crown
|
T
Root
|

A body is identified by comparing **teeth and bone structures of the body** to the **dental records** of the suspected individual.



A body is identified in **3 steps**:

1. Postmortem examination of the body
2. Locating the antemortem dental records
3. Comparing the body to the dental records





Postmortem Examination:

May examination teeth while in the body
(if body needed for funeral)

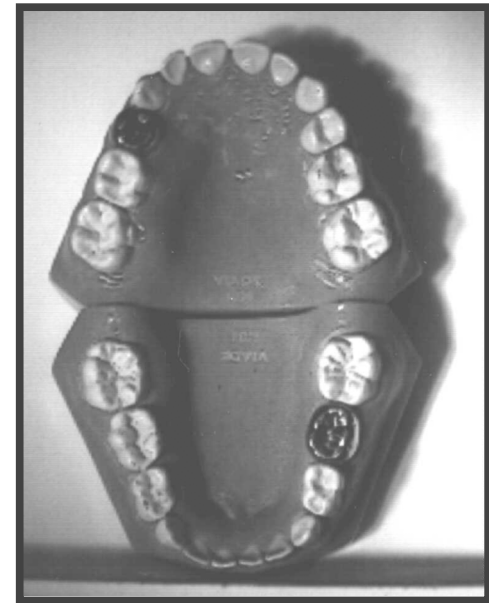
or

May remove jaw (using bone saw) and
remove soft tissue using hydrogen
peroxide.

Postmortem Examination

Each tooth or socket is examined individually and the following is recorded:

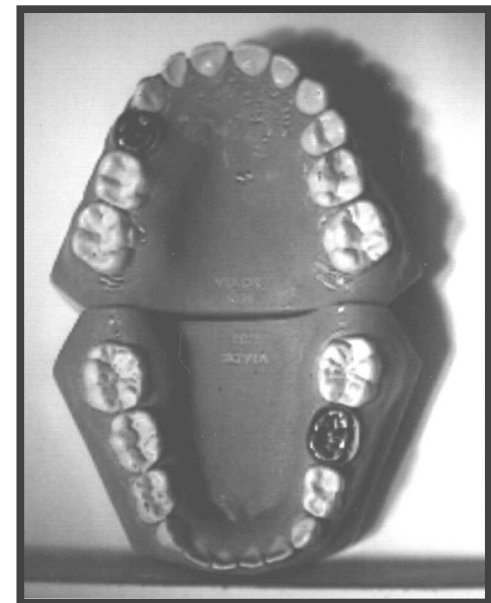
1. Presence/absence of tooth
2. Socket present or healed
 - Healed socket = past removal
 - Present socket = recent removal
3. Erupted vs. Unerupted
4. Filling or Crown Material



Postmortem Examination

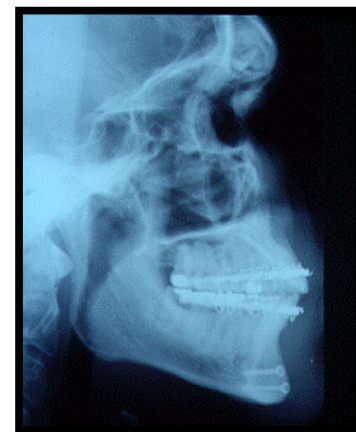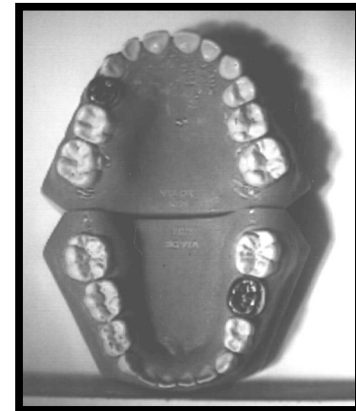
Each tooth or socket is examined individually and the following is recorded:

Also record any diseases and the general anatomy.



Postmortem Examination

After examination of teeth,
they should be
photographed and **X-rays**
should be taken.





Antemortem Records

If body is known, dental records can usually be recovered from his or her dentist.

If body is unknown, the examination results are submitted to a missing person registry.



Comparison

Postmortem exam compared to antemortem records.

A statement is made about each tooth:

Consistent

Different with explainable differences

Different with no explanation

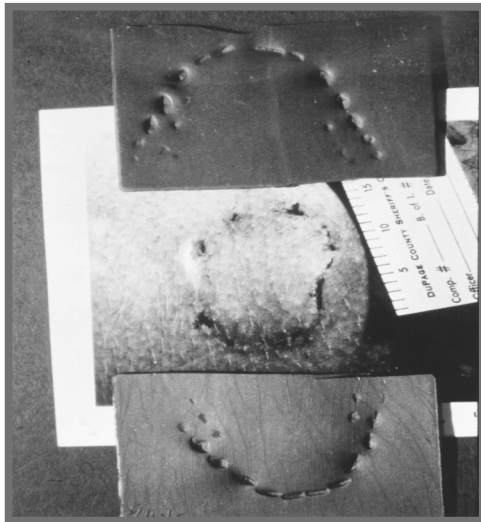


Identification in Mass Disasters:

Split into 4 teams. Run by Chief Forensic Dentist.

1. Recovery at disaster scene.
2. Postmortem exams at morgue.
3. Collect antemortem dental records.
4. Comparisons with computer software.

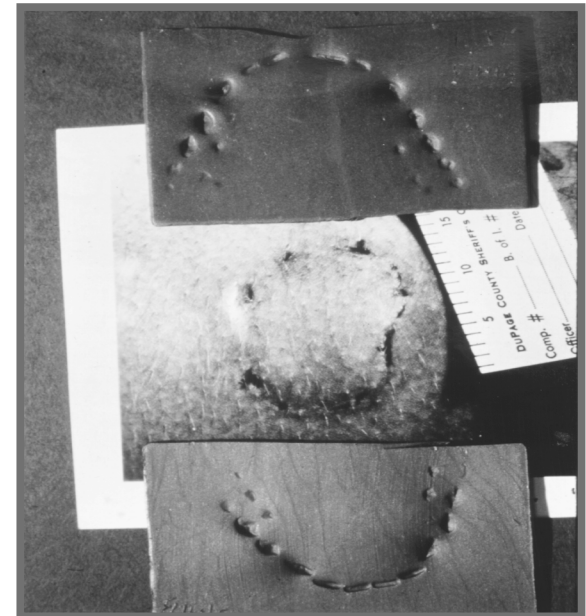
Characteristics of Bite Marks:



- Usually shape of two half moons (upper/lower)
- Usually composed of 6 upper / 6 lower teeth

Characteristics of Bite Marks:

- Antemortem (diffuse bruise)
Perimortem (defined bruise)
Postmortem (no bruise)
- Only persists 8 hours on living person

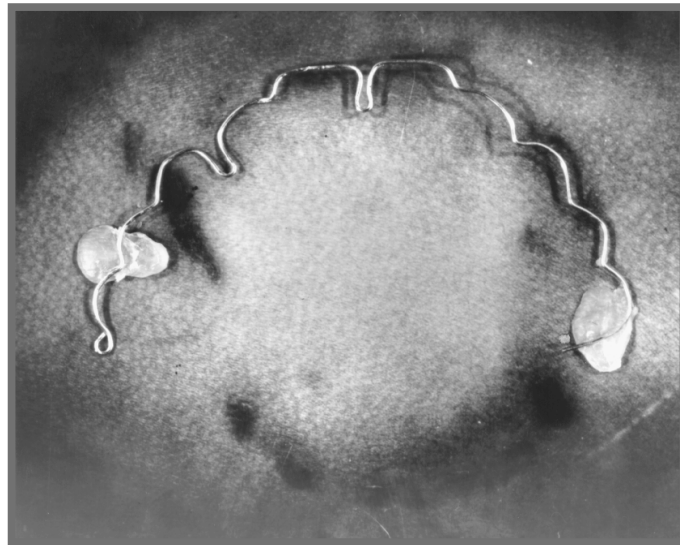




Collection of Bite Marks

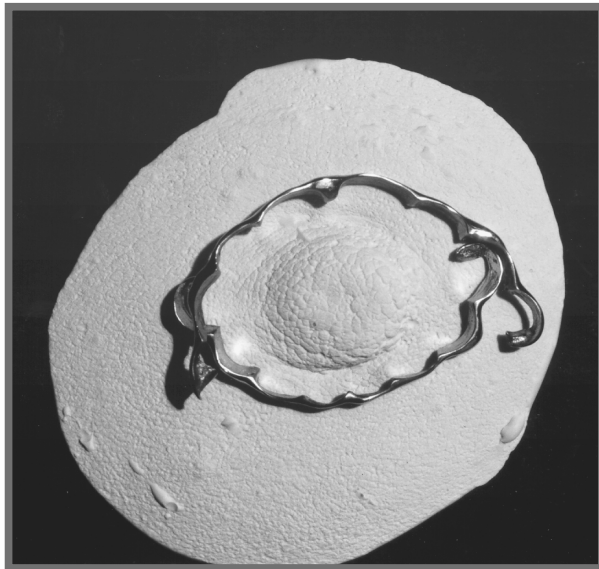1. Identify as potential bite mark
2. Collect 3 swabs
 - ABO blood test, amylase detection
 - DNA analysis
 - Microorganism analysis
3. Photograph bite mark
4. Make an impression of bite mark

Comparison of Bite Marks:



1. Photographic overlay of suspect's teeth and bite mark.

Comparison of Bite Marks:



2. Compare mold of suspect's teeth to bite mark or impression of bite mark.